

Taenia solium and Taenia  
saginata

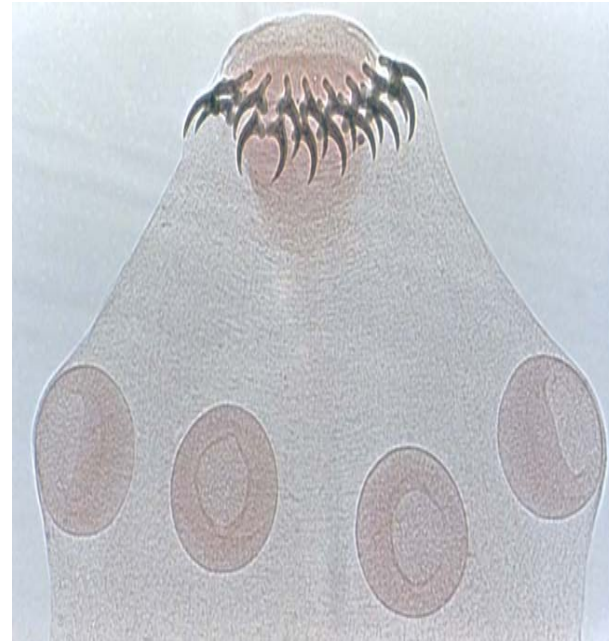
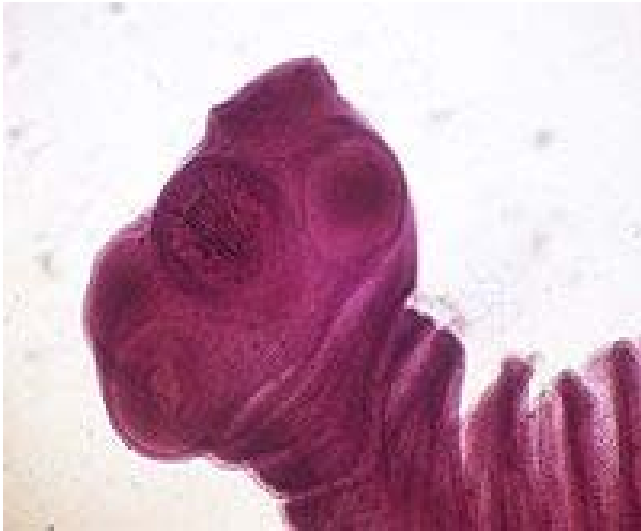# Taenia solium

- The common name for *Taenia solium* is pork tapeworm i.e the armed tapeworm of man.
- The restellum resembles the conventional figures of the sun, hence the name “solium”.
- It is worldwide in distribution
- The infection is common amongst those eating raw or insufficiently cooked measly pork.
- It is uncommon in Jews and Mohammedans who are not generally pork eaters.

# Contd.

- Adult worm lives in the small intestine of man.
- **Morphology-Adult worm**
- It measures about 2 to 3 metres in length.
- The scolex measures 1mm in diameter.
- The scolex is globular in outline and has 4 circular suckers.
- The head is provided with a rostellum armed with a double row of alternating large and small hooklets.
- The rostellar hooklets are shaped like daggers or Arabian poniards.

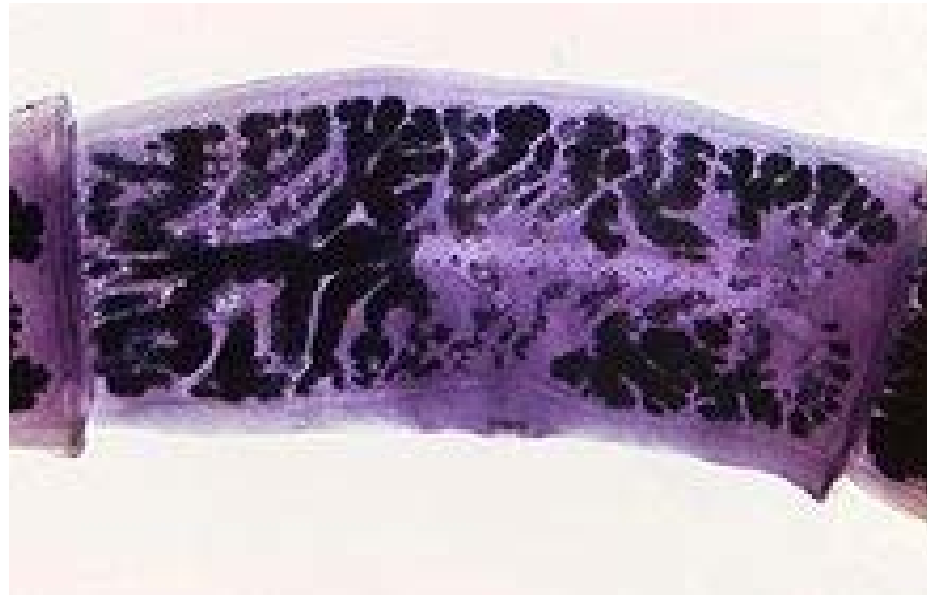# Scolex of *T.solium*

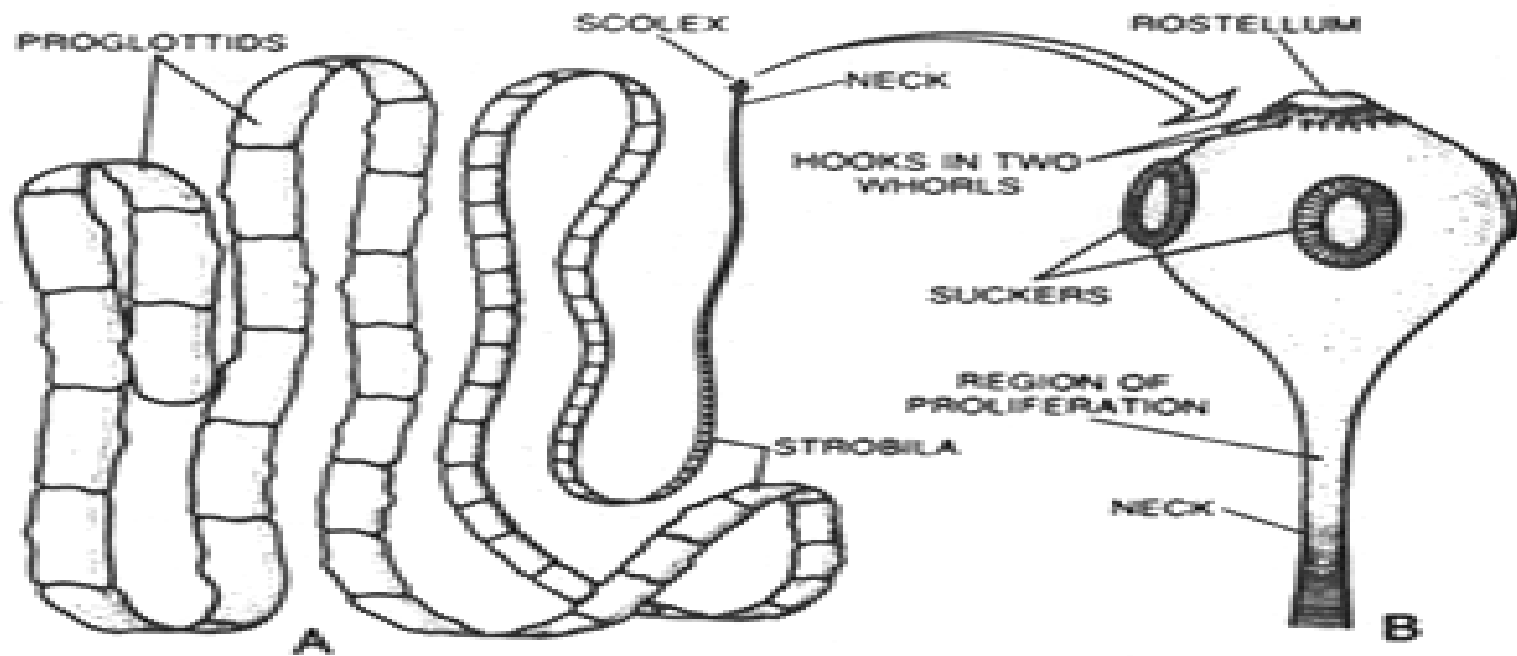


# Contd.

- The neck is short, measuring from 5 to 10 mm in length.
- Proglottides- The total number is less than a thousand.
- A gravid segment measures 12mm by 6mm.
- The gravid uterus consists of a median longitudinal stem with 5 to 10 compound lateral branches on each side.
- The gravid segments are expelled passively, in chains of 5 to 6 at a time, and not singly.

# Gravid proglottides of *T.solium*





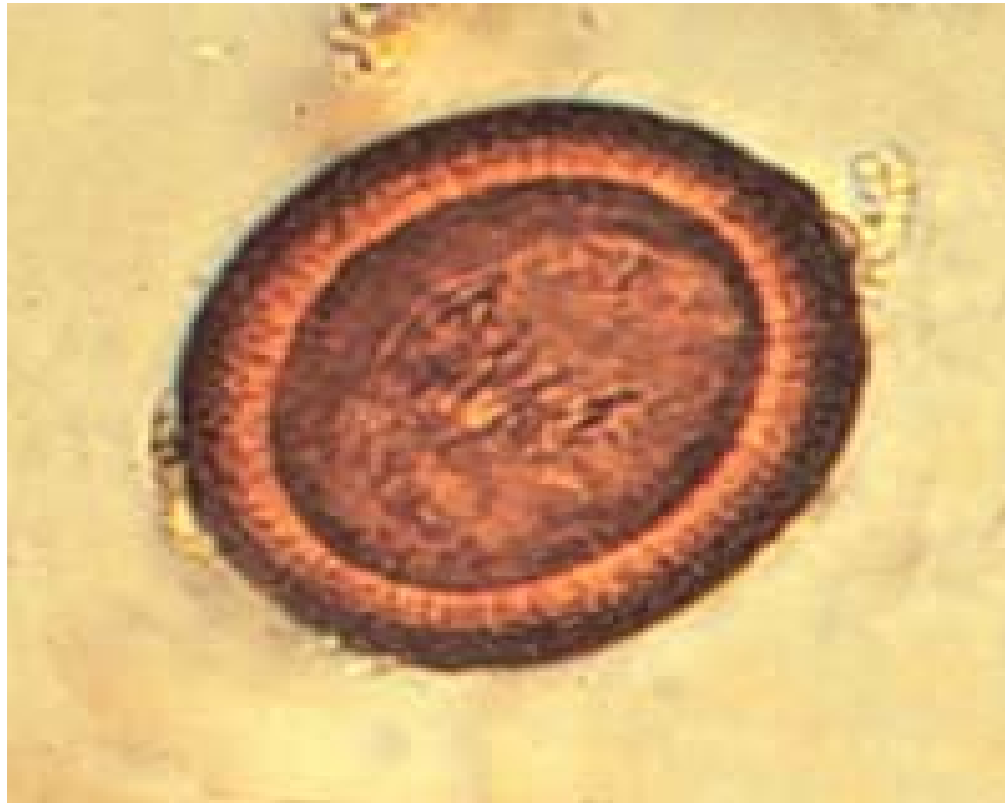*Taenia solium* : A. whole; B. its scolex

# Contd.

- The worm has a life span of as much as 25 years.
- **EGGS-** The characteristics of eggs are as follows:
  1. Spherical and brown in colour.
  2. Measures 31-43 $\mu$ m in diameter.
  3. The thin, outer transparent shell, when present, represents the remnant of the yolk mass; it causes the eggs to clump together.
  4. The inner embryophore is brown, thick walled and radially striated.
  5. It contains an oncosphere (14 to 20 $\mu$ m in diameter) with 3 pairs of hooklets.
  6. Does not float in saturated solution of common salt.
  7. Eggs are resistant and may remain viable for 8 weeks.
  8. Eggs are infective to pig as well as to man.



# Egg



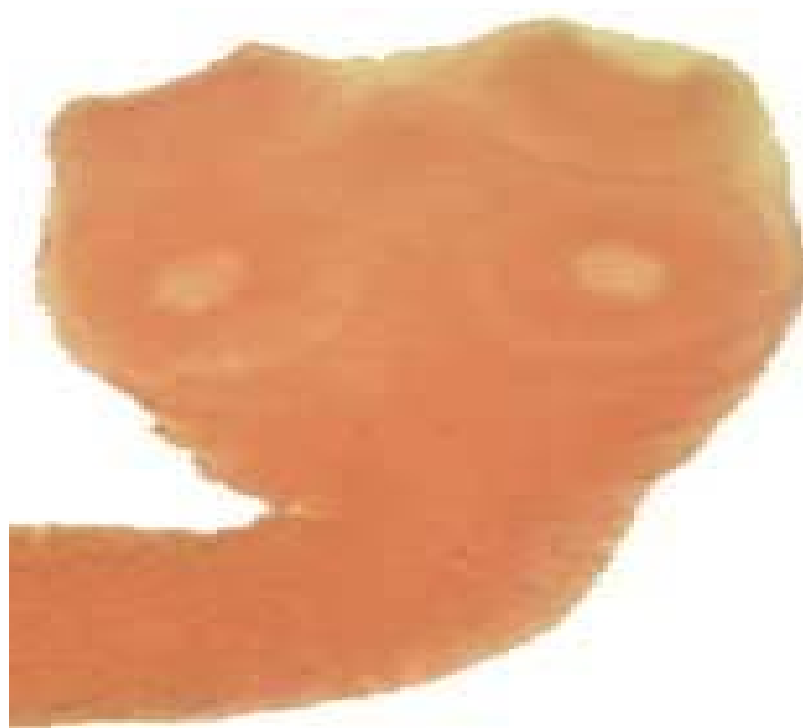# Taenia saginata

- The common name is beef tapeworm; the unarmed tapeworm of man.
- It is worldwide in distribution.
- In India, it is particularly prevalent amongst Mohammedans.
- But is not generally found amongst Hindu community who do not as a rule eat beef.
- Adultworm lives in the small intestine of man.

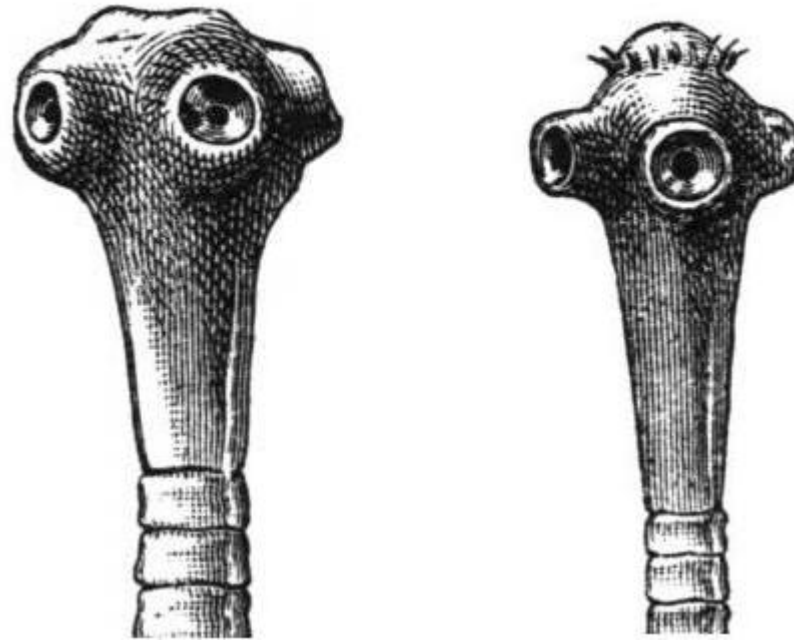
# Contd.

- **Morphology-Adult worm**
- It is white and semitransparent, measuring 5 to 10 meters in length but it may be upto 24 metres.
- The scolex measure 1 to 2 mm in diameter, is quadrate in outline and has 4 circular suckers.
- The head is not provided with any rostellum or hooklets.
- Adult worm moves against the peristaltic movement in the host's intestine.

# Scolex of *T.saginata*



# Scolex of *T.saginata* and *T.solium*

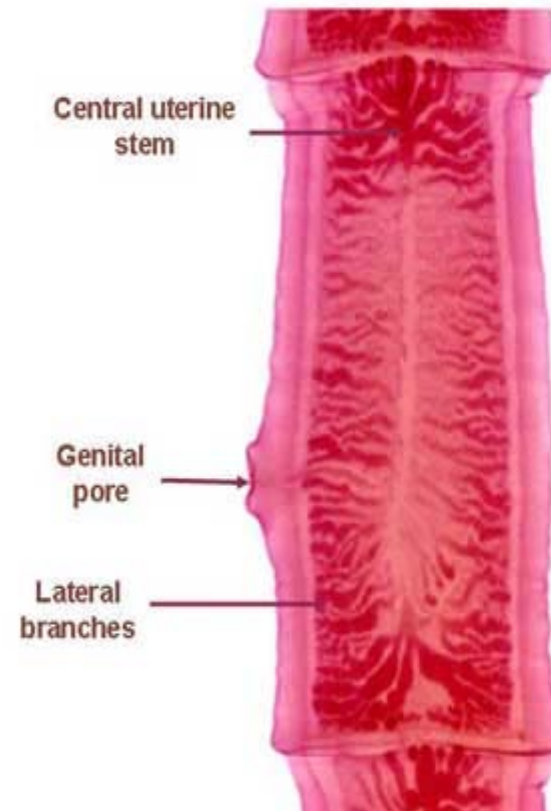


# Contd.

- The neck is fairly long and narrow. It is fragile.
- Proglottides- The number varies 1,000 to 2,000.
- The length of a gravid segment is 3 to 4 times its breadth.
- When relaxed, the terminal gravid segment measures about 2 cms in length by 0.5 cm in breadth.
- The gravid segments are expelled singly and may force their way through the anal sphincter often showing great activity outside.

## *Taenia saginata* gravid segment

- The gravid proglottides are longer than wider (16-20 X 5-7mm) with 15 to 20 lateral branches on each side of the central uterine stem.



# Contd.

- The life span of the adult worm is considerable, it may live for upwards of 10 years.
- Eggs – As there is no uterine opening , the eggs are liberated by the rupture of ripe proglottides.
- Eggs are infective to cattle only.
- Rest of the characteristics of the egg are same as those for T.solium.



# Egg



## Adult worms of *T.saginata* and *T.solium*

	<b><i>T.saginata</i></b>	<b><i>T.solium</i></b>
Length	5 to 10 metres	2 to 3 metres
Head	Large,quadrate,without rostellum and hooks,suckers may be pigmented	Small,globular with rostellum and hooks, suckers not pigmented
Proglottides		
Number	1000 to 2000	Below 1000
Expulsion	Expelled singly and may force anal sphincter	Expelled passively in chains of 5 or 6
Uterus	Lateral brances 15 to 30 on each side,thin and dichotomous.	Lateral branches 5 to 10 on each side, thick and dendritic
Vagina	Vaginal sphincter present	Vaginal sphincter absent
Ovaries	2 in number,without any accessory lobe	2 in number, with an accessory lobe
Testes	300 to 400 follicles	150 to 200 follicles.

# Contd.

- **Life cycle of T.saginata**-The worm passes its life cycle in two hosts:
  1. The definitive host:man which harbours the adult worm.
  2. The intermediate host: Cattle which harbours the larval stage.
- The adult worm lives in the small intestine of man.
- The eggs or gravid segments are passed out with the faeces on the ground.
- The animals swallow these eggs while grazing in the field.
- On reaching the alimentary canal of the intermediate host, the radially striated walls of the eggs rupture and oncospheres are liberated.

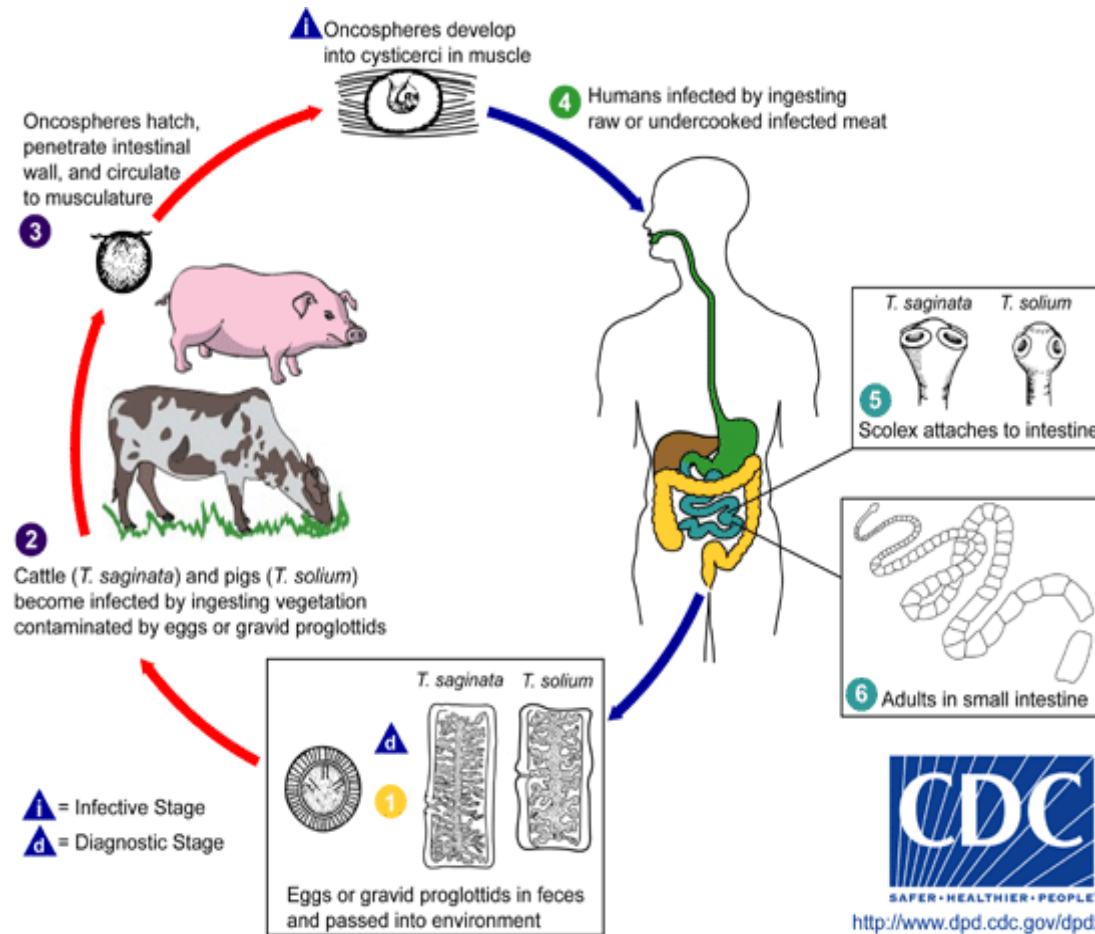
# Contd.

- These penetrate the gut wall with the aid of their hooks and gain entrance into the portal vessels or mesenteric lymphatics then to the systemic circulation.
- The naked oncospheres are filtered out from the circulating blood into the muscular tissues.
- Ultimately they settle down in the muscular tissue and undergoes further development.
- The oncospheres lose their hooks on reaching their destination.
- It takes about 60 to 70 days for the oncospheres to metamorphose into the cysticercus stage.

# Contd.

- Human beings are infected through the eating of undercooked beef containing the cysticerci.
- Inside the alimentary canal of man, the scolex, on coming in contact with the bile, evaginates and anchors to the gut wall by means of its suckers.
- It develops into an adult worm by gradual strobilisation.
- The worm grows to sexual maturity in 2 to 3 months and starts producing eggs.
- These eggs passed in the faeces along with the gravid segments, thereby repeating the cycle.

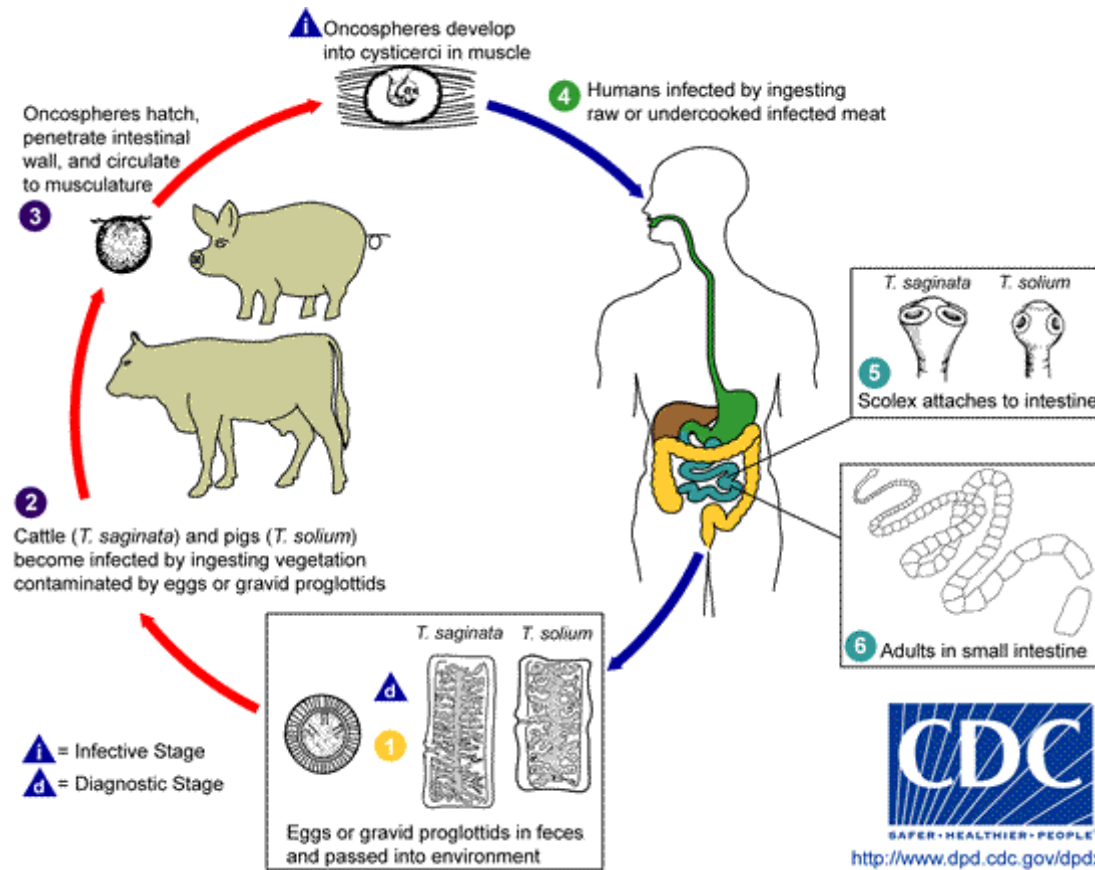
# Life cycle of *T.saginata*



# Contd.

- **Life cycle of T.solium**-The intermediate host is the pig.
- Human beings are infected through the eating of undercooked pork, containing the cysticerci.

# Life cycle of *T. solium*

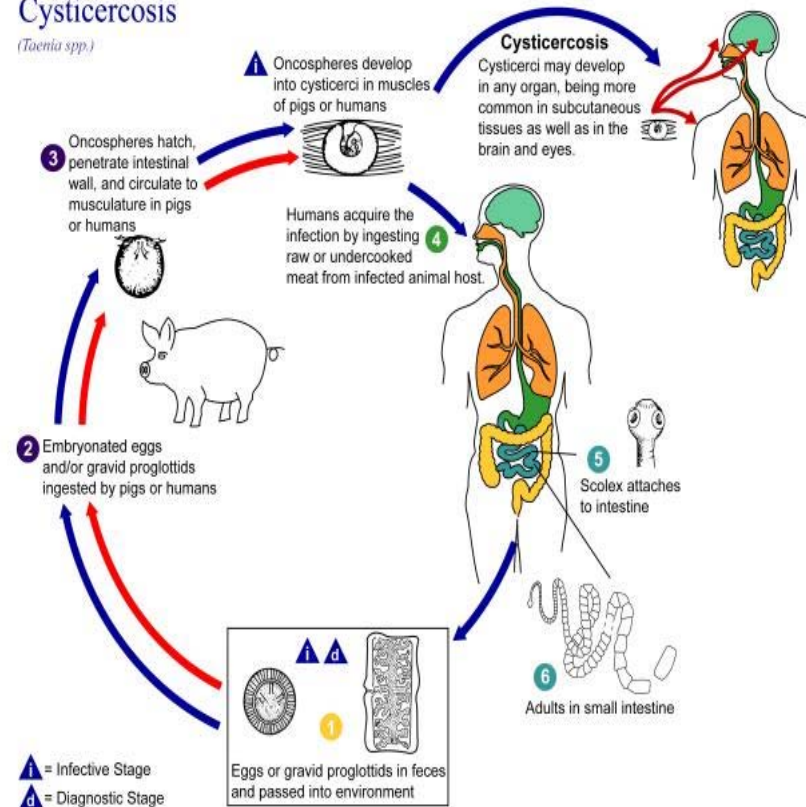




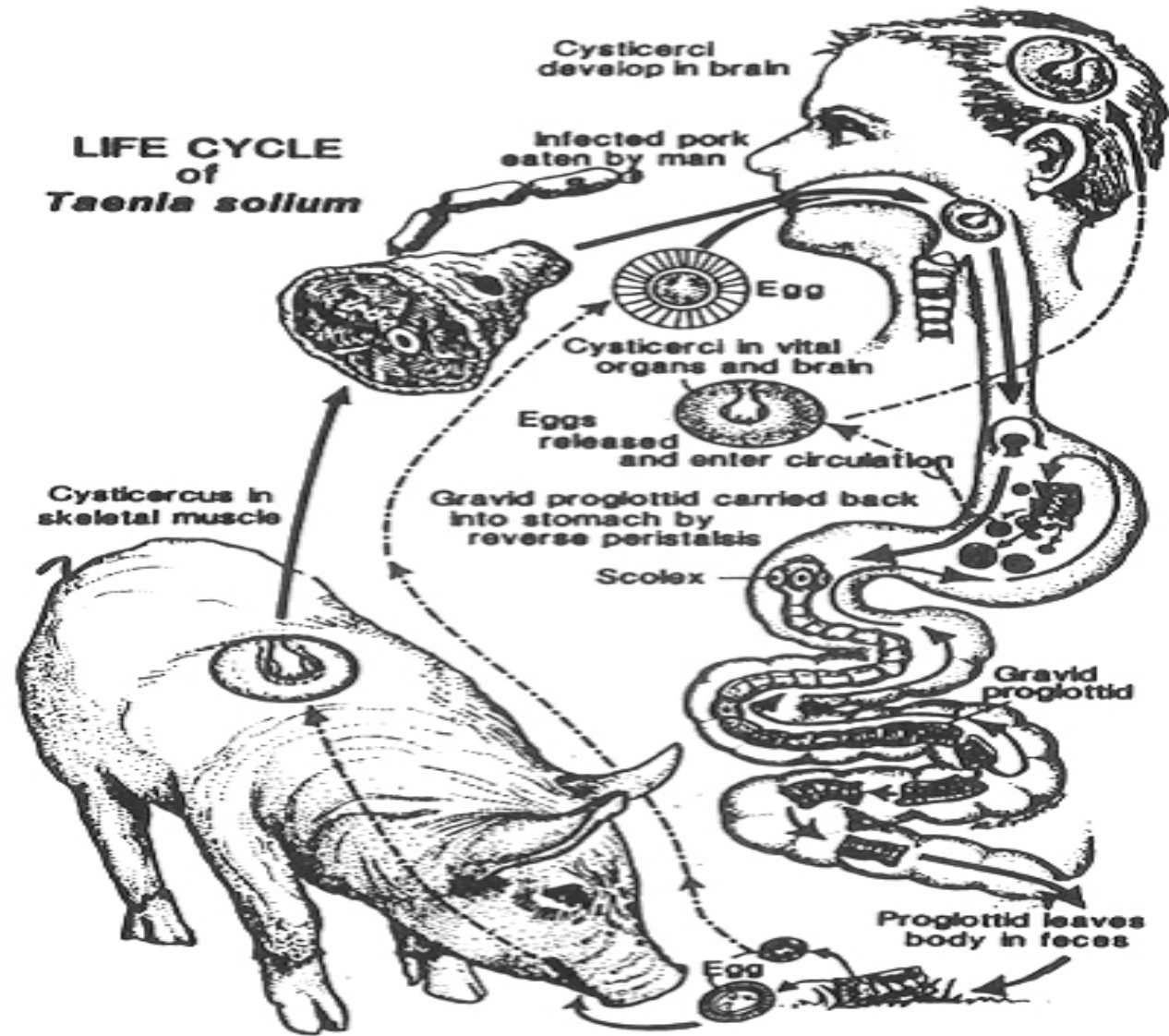
# Life cycle

## Cysticercosis

(*Taenia spp.*)



**LIFE CYCLE  
of  
*Taenia solium***



# Larval development of *T.saginata* and *T.solium*

- **Cysticercus bovis**-This is the larval stage of *T.saginata* developing in the muscles of a cow or a buffalo.
- It measures 5 to 10 mm in breadth by 3 to 4 mm in length.
- It contains an unarmed scolex invaginated at one side.
- It can live for about 8 months in the flesh of cattle.
- It can only develop further when ingested by man, its definitive host.
- *Cysticercus bovis* does not occur in man.

# Contd.

- **Cysticercus cellulosae**-This is the larval stage of *T.solium* developing in the muscles of the pig.
- A mature cyst is an opalescent ellipsoidal body.
- It measures 8 to 10mm in width by 5mm in length.
- The long axis of the cyst lies parallel with the muscle fibre.
- There is a dense milk white spot at the side where the scolex with its hooks and suckers remain invaginated.

# Contd.

- The cyst contains a fluid rich in salt and albuminous material.
- It can live for about 8 months in the flesh of pig.
- It can only develop further when ingested by man, its definitive host.
- *Cysticercus cellulosae* has also been found in man.

# Pathogenicity of tapeworms

- Mode of infection-By ingestion of undercooked meat of the intermediate hosts:
  - a. In *T.saginata*-Beef, containing *Cysticercus bovis*.
  - b. In *T.solium*-Pork, containing *Cysticercus cellulosae*.
- Adult worms while living in the intestine usually do not give rise to any symptoms.
- Occasionally they may be responsible for vague abdominal discomfort, chronic indigestion, anaemia and intestinal disorders.

# Contd.

- Larval worms of *T.saginata* are not found in man but those of *T.solium* may occasionally be found.
- **Cysticercus cellulosae**-Man becomes infected either by drinking contaminated water or by eating uncooked vegetables infected with the eggs.
- A man harbouring the adult worm may auto-infect himself either due to unclean and unhygienic personal habits or by a reversal of peristaltic movements of the intestine.
- The cysticerci may develop in any organ and the effect produced depends entirely on the location of the cysticerci in the body.

# Contd.

- The distribution of these cysticerci is usually in the subcutaneous tissues and muscles.
- These are causing palpable or visible nodules but may be found in the brain leading to epileptic attacks.
- *Cysticercus cellulosae* in the eye is diagnosed by ophthalmoscopic examination.
- The *Cysticercus* have a tendency to become calcified and obsolete in the course of 5 to 6 years.



# Diagnosis of Tapeworm infection

- This is carried out by the examination of stool.
- At first a naked eye examination of the specimen should be made for segments.
- The whitish segments can easily be recognised against the dark yellow mass of the faeces.
- If the specimen is obtained after an anthelmintic, the sample of faeces may be screened and examined macroscopically for the “head”.

# Contd.

- A microscopical examination of the stool for the eggs of the adult worm is carried out by-
  - i. A direct smear preparation of the sample of faeces.
  - ii. A smear preparation made from the sample after concentrating in one of the low density solutions.
- A perianal swab(NIH) for the demonstration of eggs may sometimes be helpful in the diagnosis of T.saginata infection.
- **Species diagnosis**-The eggs of T.saginata cannot be differentiated from the eggs of T.solium.
- The “head” and the gravid segment are the only means of establishing a species diagnosis.

# Contd.

- **Diagnosis of Cysticercosis**-This is based on the following-
  1. Biopsy examination of a subcutaneous nodule containing cysticerci.
  2. Roentgenograms of skull and soft tissue may reveal calcified cysticerci.
  3. Eosinophilia may occur in the invasive stage.
  4. A positive indirect haemagglutination test using antigen from pig's cysticerci.
  5. A history of intestinal taeniasis often helps in the diagnosis.

# Treatment

- Praziquantel and niclosamide can be used for the treatment of human tapeworm infection.
- A single dose of four tablets of niclosamide is effective against adult *T.saginata* and *T.solium* in the intestine.
- However for the treatment of *T.solium* infection praziquantel is the drug of choice.
- Because praziquantel not only kills the adult tapeworm in a single dose, but when taken in high doses over 3-7 days kills the cysticerci too.

# Contd.

- To readily eliminate the segments from the bowel, a purgative may be given 1-2 hours after anthelmintic treatment.
- The patient must be instructed for careful washing of hands after defecation and for safe disposal of faeces for at least four days following therapy.

# Prophylaxis of T.saginata infection

- All beef to be eaten by man should be inspected for cysticerci.
- Through cooking of beef ensures complete protection.
- Proper sanitary disposal of faeces.
- In order to break the parasitic life cycle, infected people should be treated.

# Prophylaxis of T.solium infection

- Personal hygiene.
- General sanitary measures.
- Avoid food and water contamination with T.solium eggs.
- Strict veterinary inspection of pork in all slaughter houses with condemnation of “measly pork”(infected pig).
- Thorough cooking of pork ensures complete protection.
- Pickled or salted pork is not necessarily safe.
- Pigs should not have access to human faeces.
- Avoid eating raw vegetables grown on soil irrigated by sewage water.
- In order to break the parasitic life cycle, infected people should be treated.